



Dr. Nikos Mattheos
DDS, MASc, PhD



Lecture notes:

Impact of Restorative Design and Choices on Clinical Outcomes and Long-term Success of Implant Therapy.

- Implant Supracrestal Complex
- Risk for Mucositis / Peri-implantitis
- Understanding the Evidence – emerging new paradigms

Learning objectives:

- What is the Implant Supracrestal complex and what are the key elements and design features with clinical importance
- How the design of the Implant-prosthesis -abutment complex can predispose to or protect from biological complications and peri-implant tissue inflammation
- How can we devise individualized maintenance strategies and use professional and patient driven maintenance to ensure long term success and health of the peri-implant tissues

Based on the presentations in Singapore, Athens, Bogotta and Lima in October/November 2022



Dr. Nikos Mattheos

DDS, MASc, PhD

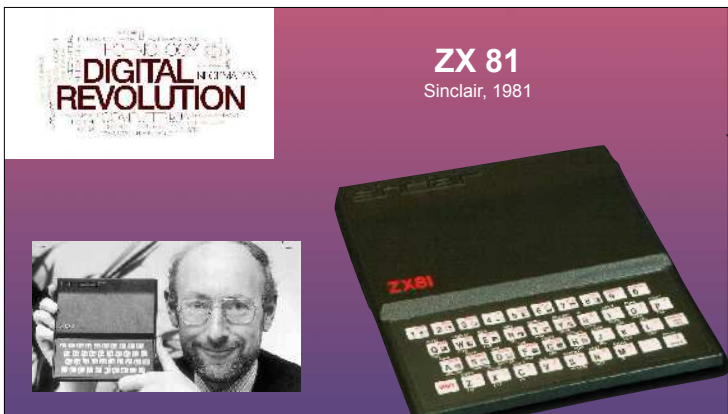
nikos@mattheos.net
www.mattheos.net

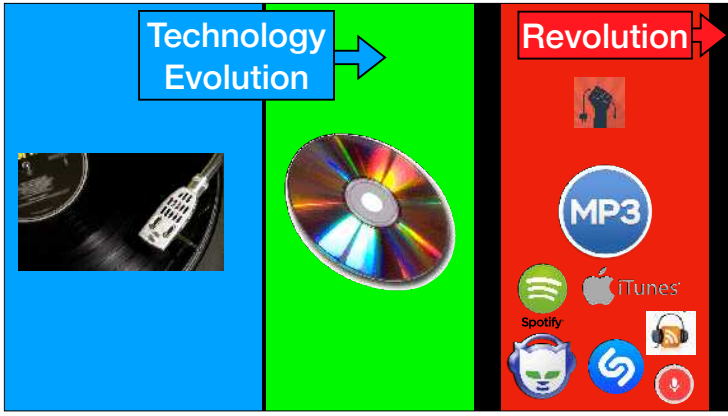


contact
m.e.

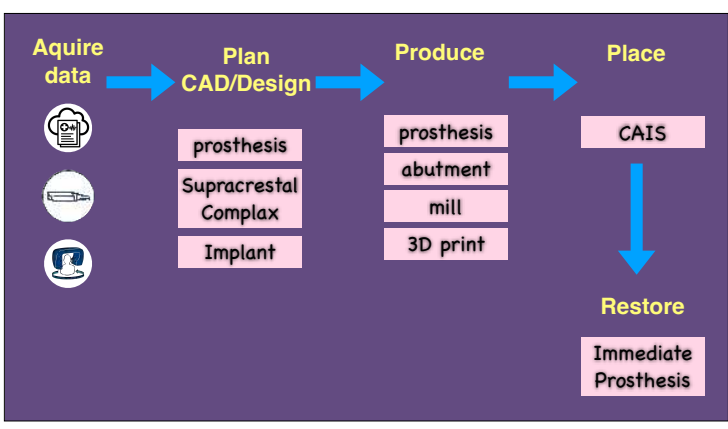


DIGITAL REVOLUTION









Prosthetic Design and Peri-implantitis
emerging paradigms and strategies

IDEM Singapore, October 2022

Can our implant choice and prosthetic design reduce the risk for long term problems and complications

- 1 What is the "transmucosal" part?
- 2 How does it link to health/disease?
- 3 How to design for long term health?

Periodontal ☑ Physiological		Peri-implant ☑ Repair tissue	
--	--	---	--

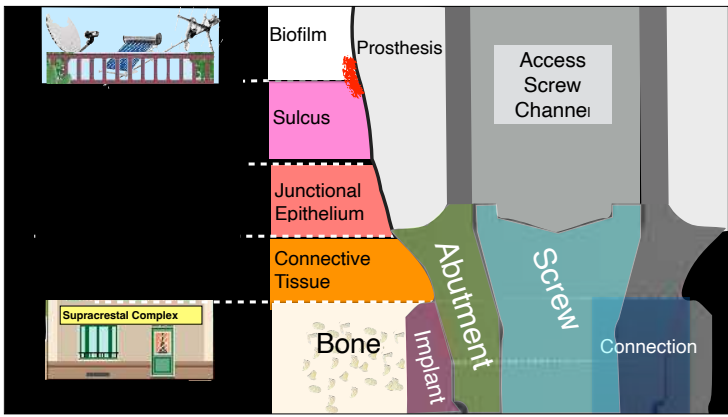
Implant

Tissue

1. Implant Supracrestal Complex

- critical components
- different tissue
- bacteria and biofilm
- anatomic structure/terminology

The Implant Supracrestal Complex and its significance for long term successful clinical outcomes.
 Mattheos, Vergoullis, Janda, Miseli Int J Pros 2021



Biomaterial

- Cervical Margin
- Emergence Profile
- Interface / Gaps
 - Impl. - Abut.
 - Abut. Prosthesis
 - Impl. - Prosthesis
- Component fit
- Cements
- Material

Supracrestal Complex

Tissue

- Mucosa Margin
 - Sulcus
 - Junct. Epith
 - Conn. Tissue
 - Bone



The Implant Supracrestal Complex

✓ Checkpoint 1 !

✓ A new powerful paradigm is emerging, where we can visualise and **design** the final treatment outcome as one system

✓ where **human tissue**, **mechanical componets** and **bacteria** interact in a complex balance.

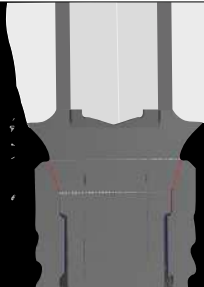
✓ **Design matters!** Our choices can impact long term stability



2. Tissue & Design elements

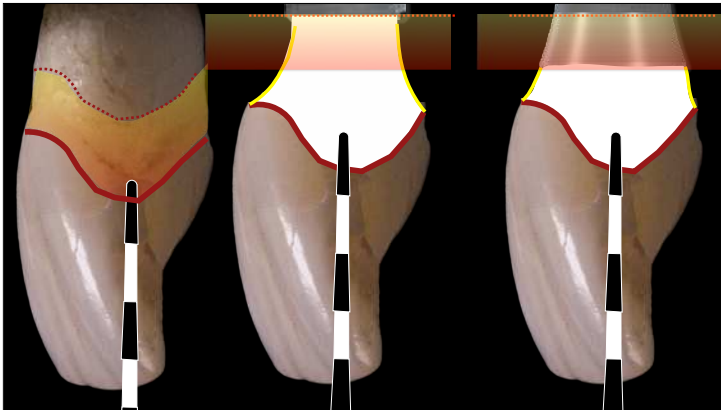


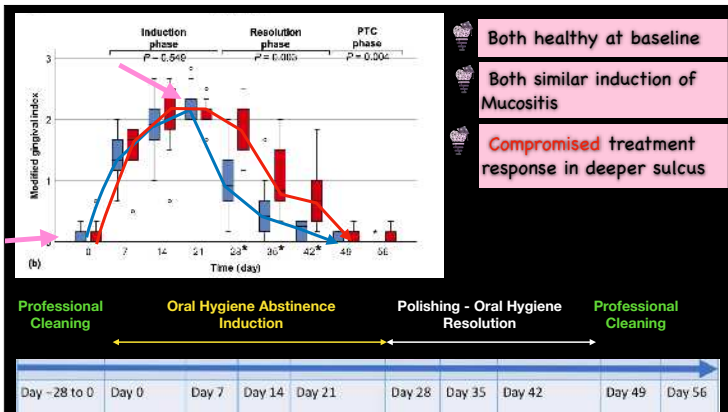
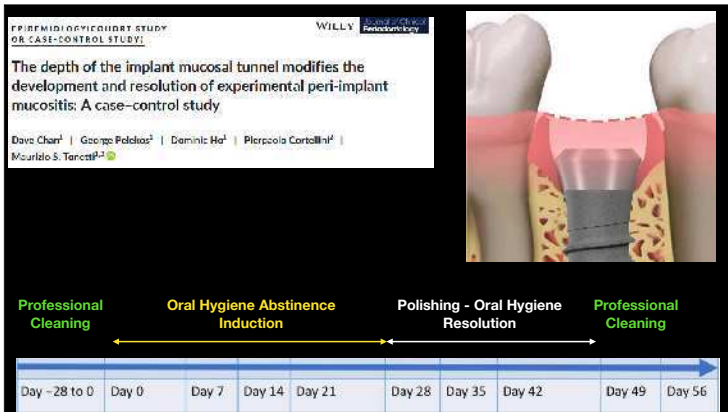
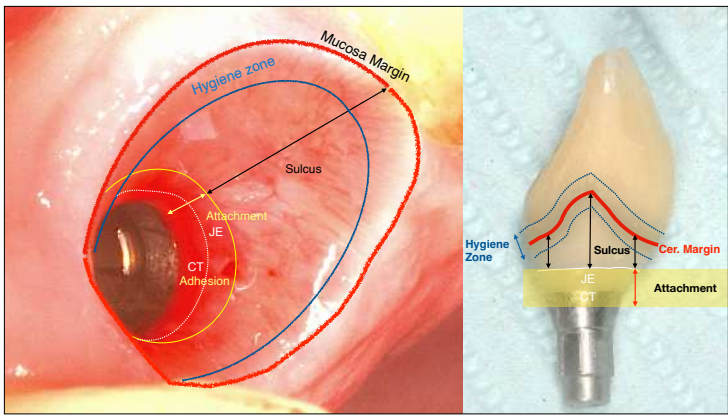
- Soft Tissue Height
- Emergence Profile & Angle
- Tissue Level / Bone Level
- Access for Oral Hygiene
- Material
- Junctions
- Retention (screw / cement)



Impact of design elements of the implant supracrestal complex (ISC) on the risk of peri-implant mucositis and peri-implantitis: A critical review

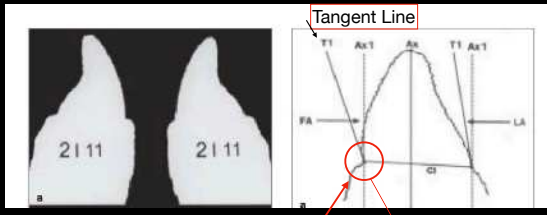
N. Mattheos et al COIR 2021



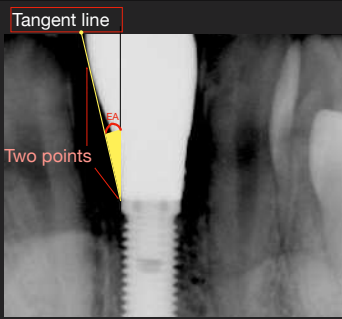


What is the Emergence Angle?

Calculation of Emergence Angle by Yongnuengnit et al 2008
on teeth



Gingival Margin one, narrow point of reference: Gingival Margin

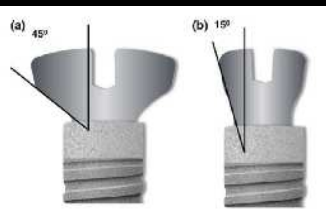


Emergence? Soft tissue?
2D vs 3D ?
TL vs BL ?

"Overcontouring"
from the bone level

Kalafuchi et al, 2018, Yi et al, 2020, Majzoub et al 2020

ORIGINAL RESEARCH | WILEY | <https://doi.org/10.1002/jbm.b.14500>
Histological and micro-CT analysis of peri-implant soft and hard tissue healing on implants with different healing abutments configurations
André Barbisan Souza¹ | AbdulMonem Alshihri^{1,2} | Peer W. Kämmerer² | Mauricio G. Araújo³ | German O. Gallucci²



4 beagle dogs	
wide abutment 45°	narrow abutment 15°
4 months	Histomorphometry

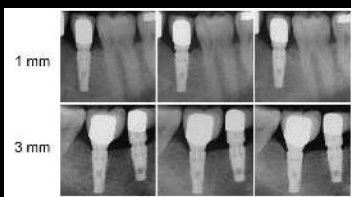
Biological width establishment around dental implants is influenced by abutment height irrespective of vertical mucosal thickness: A cluster randomized controlled trial
Spinato et al COIR 2019

70 BL/PS implants

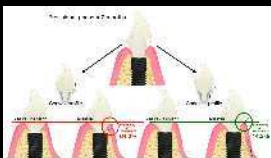
thin soft tissue (<2mm)	thick soft tissue (>2mm)
-------------------------	--------------------------

short abutment (1mm)	high abutment (3mm)
----------------------	---------------------

at restoration	3 mon	6 mon
----------------	-------	-------



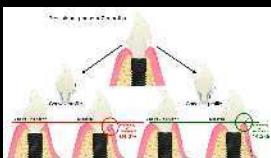
2 Emergence Profile Shape



Concave > Convex
14% >64 %
recession

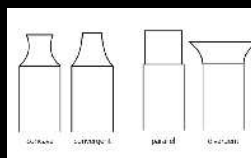
Sieghalter et al,
J Clin Perio 2022

2 Emergence Profile Shape



Concave > Convex
14% >64 %
recession

Sieghalter et al,
J Clin Perio 2022



Concave > Convex
Meta analysis
marginal bone loss

Valente et al,
I J Pros 2020




The Implant Supracrestal Complex

✔ Checkpoint 3!

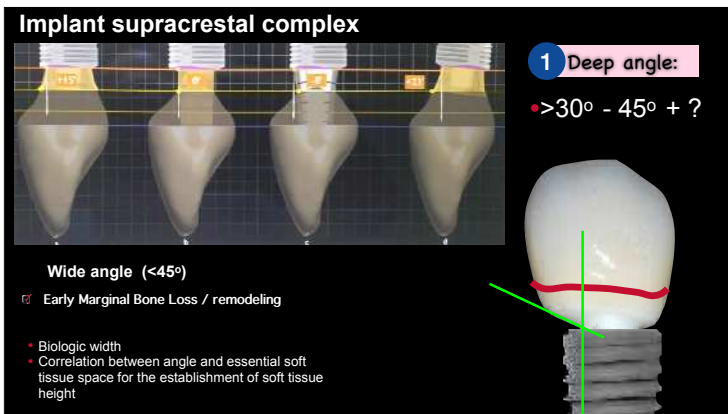
✔ "Overcontouring" appears connected with Peri-implantitis in cross sectional studies

✔ Wide angle at bone level appears connected with early marginal bone loss

✔ Convexity appears to be connected with early recession and marginal bone loss



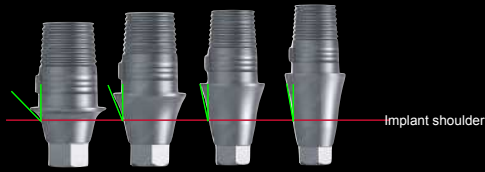
1 Deep angle:



Implant supracrestal complex

2 Soft Tissue Height

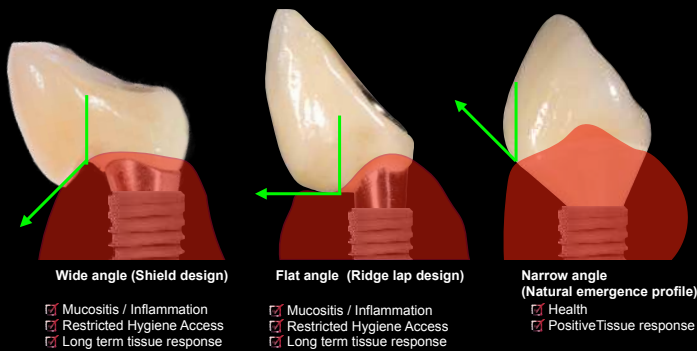
- "prefabricated" or "catalogue" abutments offer little variation in EP, EA and convexity/concavity.
- Even prefabricated abutments come with different cuff heights, thus allowing the selection of different angles for the EP.



3 Mucosal angle:

Implant supracrestal complex

3 Mucosal angle:





The Implant Supracrestal Complex

✔ Checkpoint 3!

- ✔ Stay within 30° in the **Deep angle**
- ✔ Allow for **3 - 4 mm** height to the mucosa margin
- ✔ Keep the **concave** shape from deep to mucosal angle
- ✔ Keep a **narrow** mucosal angle



Dr. Nikos Mattheos
DDS, MSc(Health inf), MASC, PhD

Thank You!



nikos@mattheos.net - www.mattheos.net

